

## Lymphatic IR for lymphatic leakage

Masanori Inoue, MD

Department of Diagnostic Radiology, School of Medicine, Keio University, Japan

### Introduction

Traumatic lymphorrhoea is a rare but potentially life-threatening complication. Post-operative lymphorrhoea is the leading cause of traumatic lymphorrhoea and can arise anywhere within the lymphatic system and manifest in various forms, from clear lymphatic fluid to chylous fluid<sup>1</sup>. Lymphangiography itself has a therapeutic effect; however, the reported therapeutic efficacy of lymphangiography for post-operative lymphatic leakage is not so high. Therefore, adjunctive embolization techniques with glue in addition to lipiodol lymphangiography is essential.

Chylothorax associated with injury of thoracic duct (TD) is a particularly difficult complication to manage. Treatment has traditionally consisted of conservative treatment and/or surgery (TD ligation, pleurodesis). Recently, thoracic duct embolization (TDE) has become a viable treatment alternative to open surgery due to its high success rate and minimal complications<sup>2</sup>. On the other hand, abdominal post-operative lymphatic leakage can manifest in various forms, from clear lymphoceles to chylous ascites or chylothorax. The standard treatment of choice is conservative treatment,

However, there are some refractory cases that require more aggressive methods, including surgery. It is easy to visualize leakage and perform embolization or sclerotherapy for lymphatic leakage from lumbar lymphatics. However, unlike chylothorax, for which thoracic duct embolization has been established as a minimally invasive treatment option, there have been only several papers of embolization for chylous ascites and there exists no standard treatment strategy.

In this presentation, we would like to introduce the procedures of lipiodol lymphangiography, adjunctive embolization techniques using N-butyl cyanoacrylate (NBCA) glue, and sclerotherapy for the management of postoperative lymphatic leakage.

### Anatomy

There are three distinct lymphatic systems that are different in function and fluid composition: liver, intestinal, and soft tissue lymphatic systems. The cisterna chyli receives lymph from the right and left lumbar trunks, hepatic lymphatics, and intestinal trunk. The TD carries 1-2 L of lymphatic fluid a day; 80% of this fluid comes from intestinal and hepatic lymphatic ducts. The TD is the largest lymphatic duct in the body, measuring up to 45 cm in length and 2 to 5 mm in diameter. The TD begins from the CC

and enters the thoracic cavity at the aortic hiatus, with the aorta on its left and the azygos vein on its right.

### **Lymphatic leakage of abdomen**

Lymphatic leakage from bilateral lumbar lymphatic can be visualized by intranodal lymphangiography. These leakages can be treated by lymphopseudoaneurysm embolization, the closest upstream lymphnode embolization, direct upstream lymphatic vessel embolization, or sclerotherapy<sup>3)</sup>. On the other hand, lymphangiography is often not able to demonstrate the source of the leak in chylous ascites. Anatomically, intestinal lymphatic ducts that carry chyle to join lumbar lymphatic ducts or cisterna chyli are often outside the pathway of the contrast that is injected in the lower extremity. Chylous ascites is difficult to treat at present<sup>4)</sup>.

### **Chylothorax**

Chylothorax results from the leakage of intestinal lymphatic fluid from the TD and its tributaries. The most common cause of chylous leak is iatrogenic, particularly thoracic or abdominal surgery. It has been reported to occur at a rate of 0.42% for all general thoracic surgery procedures<sup>5)</sup>.

Traditionally, low-output chylothorax (<1000 mL/d) is treated conservatively with total parental nutrition<sup>6)</sup>. High-output chylothorax usually mandates early surgical ligation via an open or video technique<sup>7-8)</sup>.

### **History of TDE**

TDE is developed by the fathers of Interventional Radiology, Dr. Constantine Cope. Initially, Cope tested the feasibility of TD cannulation in a porcine model<sup>9)</sup>. In his next animal experiment, the TD and cisterna chyli (CC) were lacerated and embolized with metal and platinum coils (10). In 1998, Cope published TDE results on his first five human patients<sup>11)</sup>.

### **Anatomical variation of TD and CC**

Several classifications have been developed to describe commonly seen anatomic variations. Among them, Johnson et al. described the useful anatomical variations of the TD/cisterna chyli based on clinical relevance: normal, complete left-sided course, complete right-sided course, proximal and distal duplications, plexiform variation and total absence of the cisterna chyli<sup>12)</sup> (**Fig1**).

### **Technique of TDE**

TDE consists of three parts: lymphangiography, access to the TD, and embolization of the TD.

#### **1) Lymphangiography**

The traditional procedure was bilateral pedal lymphangiography (PL), which is both time-consuming and technically challenging and remains a significant barrier to performing a TDE. Ultrasound-guided intranodal lymphangiography (IL) is alternative method to PL<sup>13, 14</sup>). Ultrasound of the groin is performed to identify suitable lymph nodes. Then, an inguinal node is directly punctured under ultrasound guidance with a 23-gauge needle. The needle tip should be positioned in the transitional zone between the cortex and hilum of the lymph node. Under fluoroscopic guidance, lipiodol is injected by hand at a rate of about 1 mL per 5 minutes.

## **2) Access to the TD**

Transabdominal direct puncture of the TD or CC is the first choice when intranodal lymphangiography confirms a normal anatomy. When an anatomical variation of the TD is revealed by IL, a safe and feasible access route should immediately be confirmed by subsequent plain CT/cone-beam CT after lymphangiography. A left-sided TD/CC or a duplicated TD located close to, or behind the aorta confers the potential risk of penetrating the aorta during direct puncture under fluoroscopy. Direct puncture of the TD would be technically demanding if IL reveals a thin TD with no cisterna chyli. Transabdominal access might be feasible in this circumstance, but the CT-guided translumbar approach should be considered. After the puncture of the TD, guidewire is inserted into the TD. Then, a microcatheter can be advanced over-the-wire proximal to the source of a chyle leak.

The transabdominal approach is difficult when patients have anatomical anomalies such as a complete left-sided TD or a plexiform variation. Therefore, the percutaneous transvenous retrograde approach via the basilica or cephalic vein through the ostial valve of the TD is an option<sup>15</sup>). With reference to lymphangiography, a 4-F or 5-F pre-shaped catheter such as a RIM should be attached to the ostial valve at the junction and then a microcatheter and a 0.016-inch guidewire can be coaxially introduced and advanced into the lower thoracic duct.

## **3) TDE**

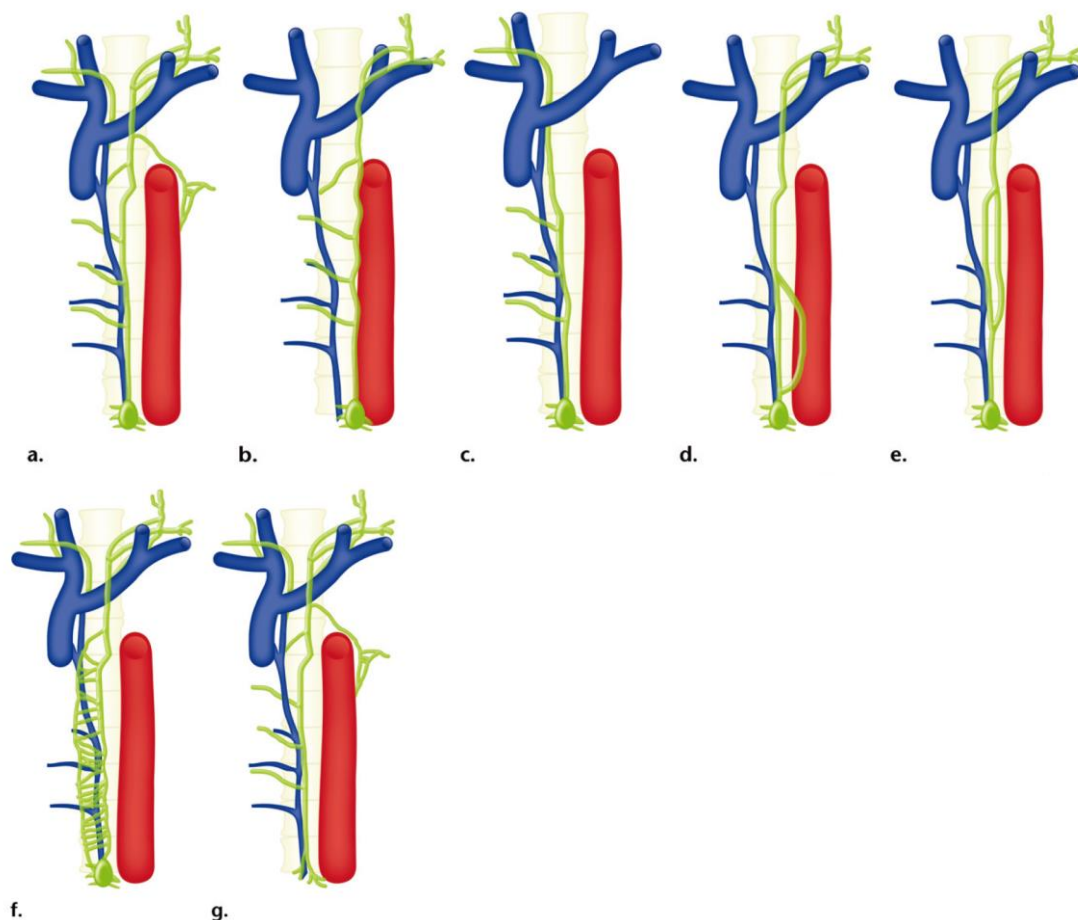
Leaks arising from the thoracic duct can be determined by lymphangiography. The leak can be stopped by embolization from the source to the cisterna chyli using coils and/or a 2:1 mixture of lipiodol and N-butyl cyanoacrylate<sup>16, 17</sup>) (**Fig. 2**).

The success rate of standard TDE procedure for post-operative chylothorax is reported to be approximately 70%<sup>16, 17</sup>).

## **Complications of TDE**

With the growing experience of TD embolization for chylothorax, complications of the procedure, although rare, are now being recognized. Itkin et al<sup>15</sup>) reported 3 minor complications out of 106 procedures, which includes asymptomatic embolization of the pulmonary artery with glue and 2 cases of leg edema and pedal suture dehiscence that resulted in wound infections. The leg edema eventually subsided, and the infections

were cured with local care and antibiotics. Laslett et al<sup>18)</sup> retrospectively evaluated the delayed complications after technically successful TDE. Mean length of follow-up was 34 months. Among 49 patients, four of 49 patients (8%) had chronic leg swelling that was probably related to the procedure, three (6%) had abdominal swelling, and six (12%) had chronic diarrhea. As for abdominal swelling, they concluded that swelling was considered to be unrelated to the procedure. In two patients with diarrhea, diarrhea was considered to result from another reason. Two of the four cases of probably-related diarrhea were severe and required medication. Given the well-known significant mortality and morbidity of an untreated chylothorax, TDE can be a feasible treatment option for chylothorax.



**Figure 1. Anatomic variations of the TD described by Inoue et al<sup>2)</sup>.**

(a) Normal course: The TD arises from the cisterna chyli at T12-L2 to the right of midline and courses cranially to enter the thorax through the aortic hiatus. The intrathoracic portion of the duct crosses the midline to the left at T5-T6, ascends above the clavicle and behind the jugular vein, then curves inferiorly to drain into the left jugulosubclavian angle.

(b) Complete left-sided course: the TD/cisterna chyli courses along the left aspect of the vertebral column throughout its entire length.

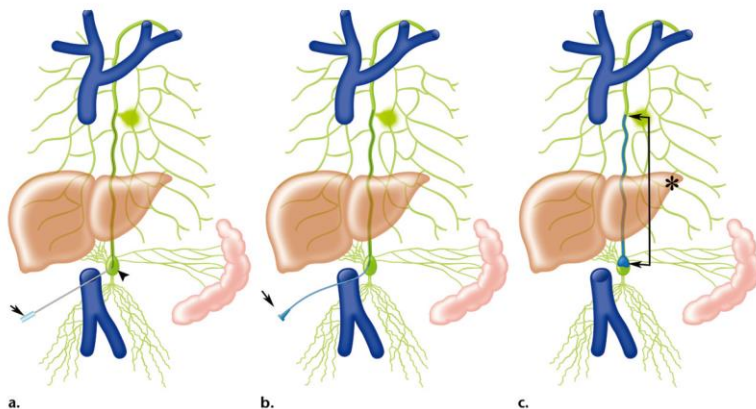
(c) Complete right-sided course: the TD/cisterna chyli courses along the right aspect of the vertebral column and drains into the right jugulosubclavian angle.

(d) Proximal duplication: the TD is partially duplicated proximally near its origin off the cisterna chyli; the two parts then join to form a single vessel that drains into the left jugulosubclavian angle.

(e) Distal duplication: the TD is partially duplicated distally; the two parts then join to form a single vessel that drains into the left jugulosubclavian angle.

(f) Plexiform variation: a plexiform variant TD, with numerous small web-like channels that eventually join and drain into the left jugulosubclavian angle.

(g) Absence of the cisterna chyli: presence of only the TD, with no cisterna chyli.



**Figure 2.** Typical procedure for transabdominal TDE described by Inoue et al<sup>2)</sup>.

(a) A Chiba needle (arrow) is advanced to the cisterna chyli (arrowhead), then a guidewire is inserted into the TD coaxially.

(b) A microcatheter alone (arrow) is inserted from the cisterna chyli to the leakage point.

(c) Embolization using N-butyl cyanoacrylate (NBCA) is performed from the leakage point to the cisterna chyli (\*; between arrows).

## References

- 1) Lee EW, et al. Lymphangiography to treat post operative lymphatic leakage: a technical review. *Korean J Radiol* 2014;15:724-732.
- 2) Inoue M, et al. Lymphatic Intervention for Various Types of Lymphorrhoea: Access and Treatment. *Radiographics*. 2016;36: 2199-2211.
- 3) Hur S, et al. Early Experience in the Management of Postoperative Lymphatic Leakage Using Lipiodol Lymphangiography and Adjunctive Glue Embolization. *J Vasc Interv Radiol* 2016. 27:1177-1186

- 4) Nadolski GJ, et al. Lymphangiography and Lymphatic Embolization for the Treatment of Refractory Chylous Ascites. *Cardiovasc Intervent Radiol* 2018. 41:415-423
- 5) Cerfolio RJ, et al. Postoperative chylothorax. *J Thorac Cardiovasc Surg* 1996. 112: 1361-1365 discussion 1365-1366
- 6) Marts BC, et al. Conservative versus surgical management of chylothorax. *Am J Surg.* 1992;164:532-5.
- 7) Christodoulou M, et al. Video-assisted right supradiaphragmatic thoracic duct ligation for non-traumatic recurrent chylothorax. *Eur J Cardiothorac Surg.* 2006;29:810-4
- 8) Merigliano S, et al. Chylothorax complicating esophagectomy for cancer: a plea for early thoracic duct ligation. *J Thorac Cardiovasc Surg.* 2000;119:453-7.
- 9) Cope C. Percutaneous thoracic duct cannulation: feasibility study in swine. *J Vasc Interv Radiol* 1995;6(4):559-564
- 10) Cope C. Percutaneous transabdominal embolization of thoracic duct lacerations in animals. *J Vasc Interv Radiol* 1996;7(5):725-731
- 11) Cope C. Diagnosis and treatment of postoperative chyle leakage via percutaneous transabdominal catheterization of the cisterna chyli: a preliminary study. *J Vasc Interv Radiol* 1998;9(5):727-734
- 12) Johnson OW, et al. The thoracic duct: clinical importance, anatomic variation, imaging, and embolization. *Eur Radiol.* 2016 ;26:2482-93.
- 13) Nadolski GJ, et al. Feasibility of ultrasound-guided intranodal lymphangiogram for thoracic duct embolization. *J Vasc Interv Radiol* 2012;23(5): 613-616.
- 14) Rajebi MR, et al. Intranodal lymphangiography: feasibility and preliminary experience in children. *J Vasc Interv Radiol.* 2011 ;22:1300-5.
- 15) Koike Y, et al. Percutaneous transvenous embolization of the thoracic duct in the treatment of chylothorax in two patients. *J Vasc Interv Radiol* 2013;24(1): 135-137.
- 16) Itkin M, et al. Nonoperative thoracic duct embolization for traumatic thoracic duct leak: experience in 109 patients. *J Thorac Cardiovasc Surg* 2010; 139:584-589; discussion 589-90.
- 17) Pamarthi V, et al. Thoracic duct embolization and disruption for treatment of chylous effusions: experience with 105 patients. *J Vasc Interv Radiol.* 2014 Sep;25(9):1398-404.
- 18) Laslett D, et al. Delayed complications following technically successful thoracic duct embolization. *J Vasc Interv Radiol.* 2012;23(1): 76-79.