

GI stent

Shunsuke Sugawara, MD

Department of Diagnostic Radiology, National Cancer Center Hospital, Japan

1. Concept

The purpose of gastro-intestinal (GI) stenting is to relieve symptoms of GI obstruction, particularly to enable and maintain oral intake with the use of stents. GI stenting is commonly performed as part of palliative care in management of malignant GI stricture. It can also be used in cases of fistula involving the bowel, thus allowing the fistula to close. Endoscopic GI stent placement by endoscopists is the most popular method of placing the stent. However, there is role for the interventional radiologists (IR) in GI stent placement via alternative access routes when endoscopy fails. For example, in cases of isolated lesions from upper and lower GI tract such as afferent loop syndrome and lesions with complicated post-operative anastomosis, percutaneous access is often the only feasible route to overcome the situation. Occasionally, the combination of both endoscopic and percutaneous access routes is required in complicated cases. In general, stent placement for the small intestine and right colon are not routinely done by the interventional radiologists because of technical difficulties.

2. Indication

- (1) Unresectable malignant GI strictures^{***}(**Figure 1**)
- (2) To restore and maintain oral intake or to allow fistula closing (**Figure 2 & 3**)^{***}
- (3) No uncontrollable coagulopathy

*In case of benign stenosis, stent placement is not allowed unless it is a retrievable or biodegradable stent. Multiple GI strictures might not be good indication for stenting.

**Stenting before surgical resection of colorectal cancer can be employed upon request on case by case basis. The clinical benefit is still controversial.

***Restoration of oral intake is expected after stenting (except in afferent loop syndrome) (**Figure 3**).

Step 1: Tubing and drainage

Dilated GI tract should be decompressed first to allow visualization of the exact anatomy and the details of stricture with contrast.

Step 2: Contrast study

Careful observation for fistula and leakage is required. Barium is contraindicated because it becomes solid and acts as a plug.

Step 3: Crossing the stricture (Figure 4)

A seeking catheter (multipurpose type) (4-6Fr) and a hydrophilic guidewire are the key combination to success. The technical tip is not only pushing and pulling, but also rotating.

Step 4: Contrast injection into the lower or upper GI

In this process, the length and character of the stricture must be evaluated, and the flow of contrast distal to the stricture site must be observed. The actual length of stricture should be measured using a guidewire or catheter.

Step 5: Exchange of the guidewire from hydrophilic guidewire to a stiff and non-hydrophilic coated guidewire

A stiff and non-hydrophilic coated guidewire should be used to avoid accidental guidewire removal. The stiffness of the guidewire also provides stability during stent delivery.

Step 6: Taking the reference images with contrast

The reference images acquired should be in the same direction as the image used during stent deployment.

Step 7: Selection of stent (bare or covered, length, flexibility and diameter).

Covered stent can prevent tumour ingrowth. However, it is slippery and has tendency to migrate.

Step 8: Advancing the stent delivery system through the stricture. (Figure 5)

The ends of the stent need to extend beyond the proximal and distal margin of the stricture.

Step 9: Decision on stent releasing point

The stent releasing point must be decided with careful consideration for foreshortening of the stent.

Step 10: Stent deployment (Figure 6)

The most important technical aspect is to keep the marker of the stent at the same point by using real-time fluoroscopy during stent deployment.

Step 11: Removal of the stent delivery system and contrast injection

The stent delivery system should be removed over the guidewire, keeping the guidewire in place. A new catheter/tube should be inserted over the guidewire until the tip extends beyond the distal end of the stent. The catheter tip is then retracted to just before the proximal end of the stent for contrast injection to assess stent opening and luminal patency.

Step 12: Removal of guidewire and a tube

The guidewire and catheter/tube must be removed after the confirmation of good passage of contrast beyond the stricture.

3. Special issues

#1 Selection of stent

Essentially, the long-term patency is better in covered stent, because it can prevent tumor ingrowth. However, it is important that the stent fits comfortably to the lumen without causing unnecessary stress to GI tract due to potential risk of bowel perforation by the stent. Additionally, the risk of stent migration caused by peristalsis must be considered especially in using a covered stent. The shape of the stent shape such as with or without flare also affects the stent selection.

#2 Combination with balloon dilatation

When the stricture is very tight, pre or post balloon dilatation is very useful. Balloon dilatation before stenting (Pre-dilatation) is also useful to evaluate the characteristics of the stricture (length, hardness, mobility, etc). Balloon dilatation after stenting (Post-dilatation) is useful to achieve the full expansion of the stent and to affix the stent firmly to the inner bowel wall. When the post balloon dilatation is needed in a stent which has potential risk of foreshortening (i.e. woven stent), the narrowest (not expanded) portion of the stent should be dilated first. In this manner, the stricture can be covered with the stent even if the stent is foreshortened. **(Figure 7)**

#3 Stent placement for afferent loop syndrome

Access routes for afferent loop in IR are 1) PTBD route and 2) percutaneous transintestinal route (direct puncture of afferent loop). Access route is decided based on the accessibility to the stenotic site and severity of bile duct dilatation.

#4 Extra-anatomical stent placement (percutaneous bypass creation)

If it is difficult to cross the stricture, a feasible alternative would be creation of new fistula by extra-anatomical stent placement between the isolated intestinal segment and adjacent intestine/stomach.

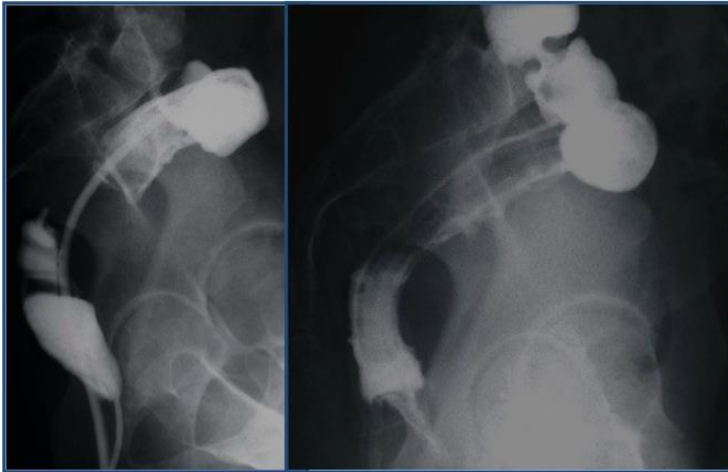


Figure 1: Rectal stent

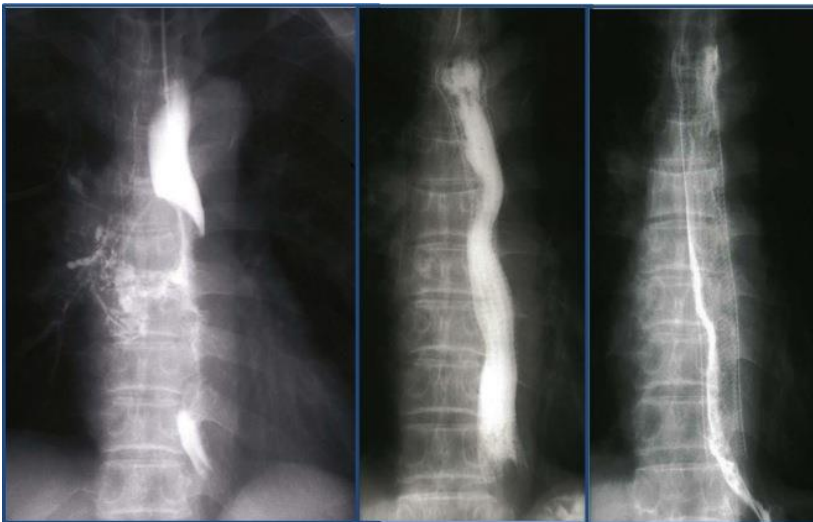

Figure 2: Esophageal covered stent for a case of esophago-bronchial fistula

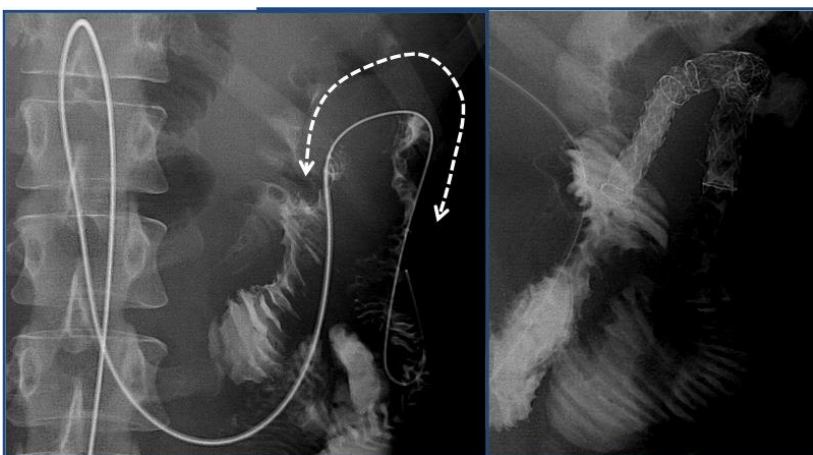

Figure 3: Stenting for afferent loop syndrome (PTBD access)

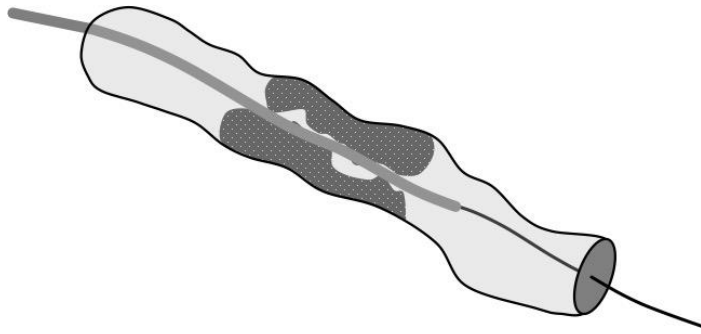


Figure 4: Crossing the stricture

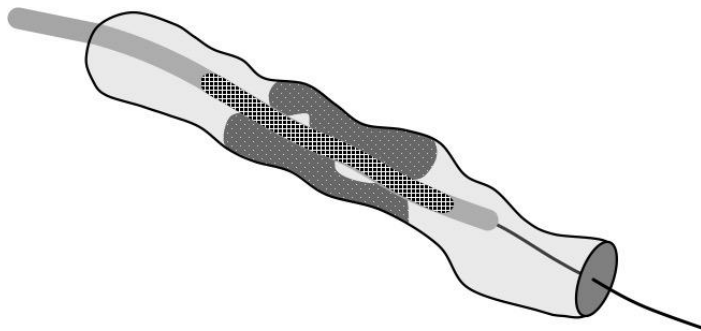


Figure 5: Advancing the stent delivery system through the stricture.

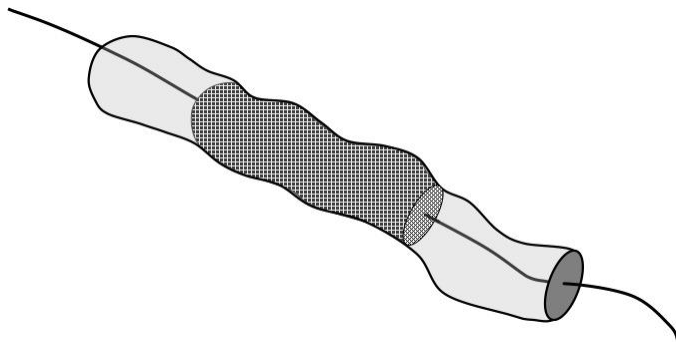
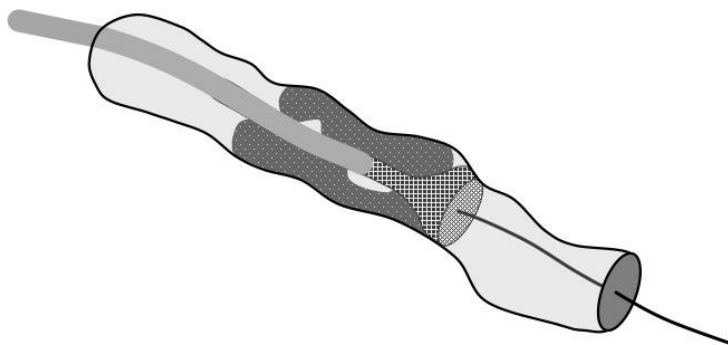


Figure 6: Stent release

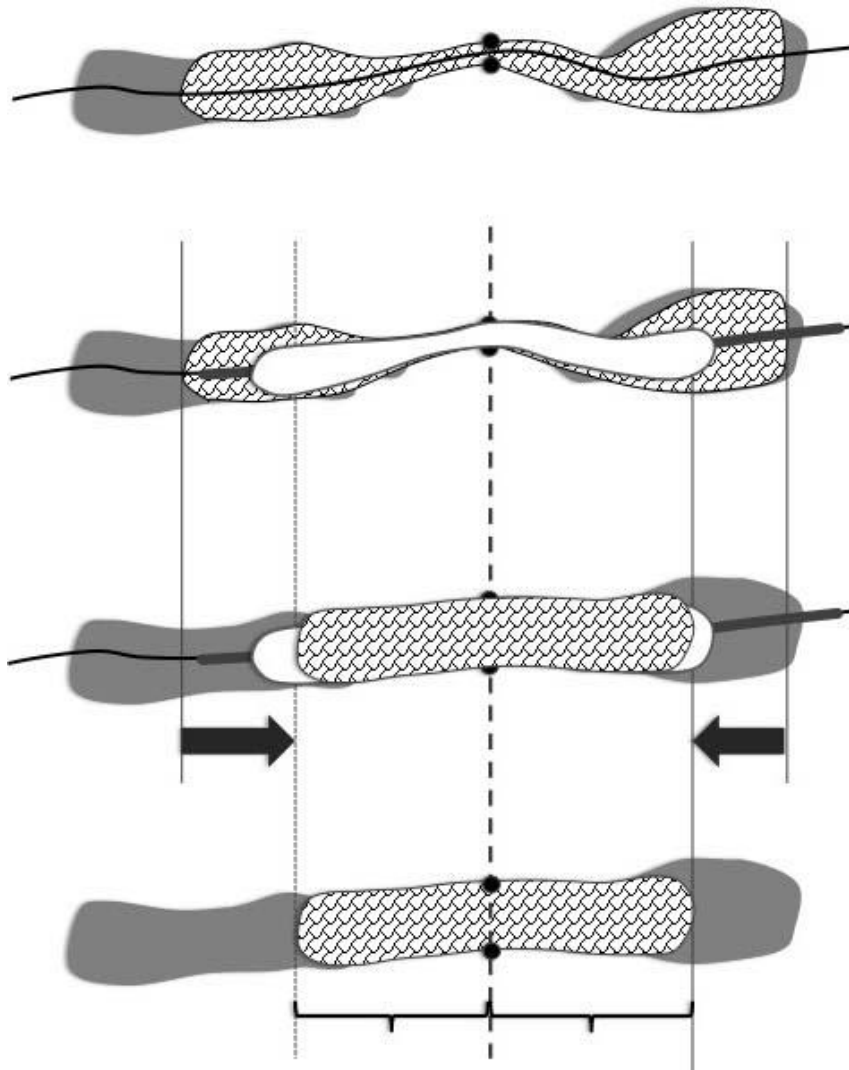


Figure 7: Foreshortening of stent with balloon dilatation

References

- 1) van Hooft JE, et al. Self-expandable metal stents for obstructing colonic and extracolonic cancer: European Society of Gastrointestinal Endoscopy (ESGE) Clinical Guideline. *Gastrointest Endosc.* 80(5):747-61, 2014
- 2) Sabbagh C et al. Is Stenting as "a Bridge to Surgery" an Oncologically Safe Strategy for the Management of Acute, Left-Sided, Malignant, Colonic Obstruction?: A Comparative Study With a Propensity Score Analysis. *Ann Surg.* 258(1):107-15, 2013.
- 3) Sato Y et al. Percutaneous drainage for afferent limb syndrome and pancreatic fistula via the blind end of the jejunal limb after pancreatoduodenectomy or bile duct resection. *J Vasc Interv Radiol* 2015;26(4):566-72
- 4) Rodrigues-Pinto E et al. Efficacy of Endoscopically Created Bypass Anastomosis in Treatment of Afferent Limb Syndrome: A Single-Center Study. *Clin Gastroenterol Hepatol.* 2016;14(4):633-7